Reproducibility of Retinal Thickness Measurements in Healthy Subjects Using Spectralis Optical Coherence Tomography

MARCEL N. MENKE, SIMEON DABOV, PASCAL KNECHT, AND VEIT STURM

• PURPOSE: To test the reproducibility of retinal thickness measurements in healthy volunteers of a new Frequency-domain optical coherence tomography (OCT) device (Spectralis OCT; Heidelberg Engineering, Heidelberg, Germany).

• DESIGN: Prospective, observational study.

• METHODS: Forty-one eyes of 41 healthy subjects were included into the study. Intraobserver reproducibility was tested with 20 × 15 degree raster scans consisting of 37 high-resolution line scans that were repeated three times by one examiner (M.N.M.). Mean retinal thickness was calculated for nine areas corresponding to the Early Treatment Diabetic Retinopathy Study (ETDRS) areas. Coefficients of variation (COV) were calculated.

• RESULTS: Retinal thickness measurements were highly reproducible for all ETDRS areas. Mean total retinal thickness was 342 ± 15 μm. Mean foveal thickness was 286 ± 17 μm. COVs ranged from 0.38% to 0.86%. Lowest COV was found for the temporal outer ETDRS area (area 7; COV, 0.38%). Highest COV was found for the temporal inner ETDRS area (area 3; COV, 0.86%). Mean difference between measurement 1 and 2, measurement 1 and 3, and measurement 2 and 3 for all ETDRS areas was 1.01 μm, 0.98 μm, and 0.99 μm, respectively.

• CONCLUSION: Spectralis OCT retinal thickness measurements in healthy volunteers showed excellent intraobserver reproducibility with virtually identical results between retinal thickness measurements performed by one operator. (Am J Ophthalmol 2009;147: 467–472. © 2009 by Elsevier Inc. All rights reserved.)

EVALUATION OF RETINAL THICKNESS HAS BECOME fundamental for diagnosing and managing various retinal diseases such as diabetic maculopathy, retinal dystrophies, central serous retinopathy, retinal vein occlusions, and age-related macular degeneration. In the past, retinal edema or atrophy could only be assessed subjectively by funduscopy. This method requires clinical experience and offers only qualitative data. In addition, exact comparisons over time are almost impossible. Successively, other techniques such as stereoscopic color photographs of the macular became available, and facilitated comparisons over time. The confocal scanning laser ophthalmoscope was one of the first instruments that allowed objective and quantitative evaluation of retinal thickness.[1]

Optical coherence tomography (OCT) was introduced 1991 as a noninvasive, cross-sectional imaging technique.[2] In 1995, time-domain optical coherence tomography (TD-OCT) was used first for imaging macular diseases.[3,4] Since than, OCT has become widely accepted for retinal thickness measurements in various retinal diseases.

Time-domain OCT uses a scanning interferometer and an 820-nm infrared light source which is split into two separate beams. One beam is scanning a tissue being analyzed, and the other one acts as a reference beam which is reflected by a reference mirror. The distance of the reference mirror can be adjusted and therefore the time it takes for the reference beam to reach the sensor can be changed. By comparing the two light beams, TD-OCT measures the optical backscattering of light to generate a cross-sectional image of the tested tissue.

Recently, improvements in OCT technology have been introduced.[5,6] Frequency-domain optical coherence tomography (FD-OCT) provides increased axial resolution and scanning speed by recording the interferometric information using a FD spectrometric method instead of adjusting the position of a reference mirror. Resolution is up to five times higher and imaging speed is up to 100 times faster than in conventional TD-OCT.[7,8] Recent studies have shown that FD-OCT is capable of imaging retinal pathologies in great detail.[9–12]

Conventional TD-OCT (Stratus OCT) provides six intersecting radial lines for macular scanning to measure retinal thickness. Attributable to the higher scanning speed, FD-OCT can perform high-density raster-scans to measure total retinal thickness or retinal nerve fiber layer (RNFL) thickness with less need of data interpolation. Recently, Spectralis OCT (Heidelberg Engineering, Heidelberg, Germany) has been introduced for retinal imaging.[13] The instrument features an eye tracking device that corrects for eye movement during the scanning process. Implementation of eye tracking should lead to highly reproducible retinal thickness measurements. Hence, the goal of this study was to test intraobserver reproducibility

Accepted for publication Sep 2, 2008.

From the University of Zurich, Department of Ophthalmology (M.N.M., P.K., V.S.), Zurich, Switzerland and the University of Muenster, School of Medicine (S.D.), Muenster, Germany.

Inquiries to Marcel N. Menke, Department of Ophthalmology, University of Zurich, Frauenklinikstrasse 24, 8091 Zurich, Switzerland; e-mail: marcel.menke@gmail.com

0002-9394/09/$36.00
doi:10.1016/j.ajo.2008.09.005

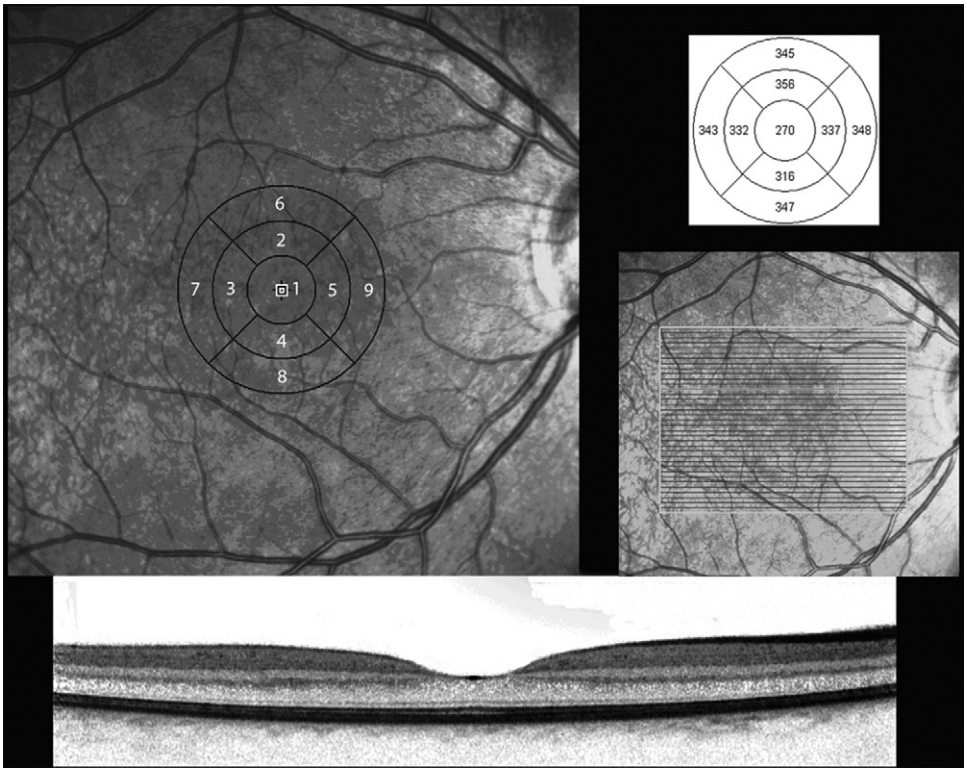

FIGURE 1. Example of a retinal thickness measurement with Spectralis optical coherence tomography (OCT) in a healthy control. (Top left) Scanning laser ophthalmoscope fundus image showing the Early Treatment Diabetic Retinopathy Study (ETDRS) plot centered on the fovea. ETDRS areas are numbered. (Top right) Corresponding retinal thickness plot. Values are given in μm. (Middle right) The rectangle indicates the scanning area. Thirty-seven B-line scans were performed. (Bottom) B-line scan centered on the fovea.

of retinal thickness measurements performed with the Spectralis OCT in healthy subjects.

METHODS

FORTY-ONE EYES OF 41 HEALTHY SUBJECTS (MEAN AGE, 28 ± 5 years; 24 females) were included into the study. Exclusion criteria were the presence of a refractive error of > ±5 diopters (D), astigmatism of > 2 D, media opacifications, a history of ocular trauma or ocular diseases affecting the cornea, lens, retina, or optic nerve. The intraocular pressure (IOP) of the study eye had to be between 11 mm Hg and 21 mm Hg. All subjects received a slit-lamp exam, fundus biomicroscopy, and indirect ophthalmoscopy prior to inclusion. In addition, the IOP was measured. Study eyes were chosen randomly. Twenty-one right eyes were included. Left eyes were treated as mirror images of right eyes for analysis. All OCT scans were performed with the Spectralis OCT, which provides up to 40,000 A scans/sec with a depth resolution of 7 μm in tissue and a transversal resolution of 14 μm by using a superluminescence diode with 870 nm bandwidth. OCT retinal thickness scans were performed three times by one operator (M.N.M.) within one session. Between measurements the subject had to lean back. Position of the headrest and OCT correction for spherical errors was readjusted between each measurement. The instrument combines OCT technology with a confocal Scanning Laser Ophthalmoscope (Heidelberg Engineering, Heidelberg, Germany), which provides a reference fundus image. Each OCT B-scan will be registered and locked to a reference image. OCT software can identify previous scan locations and "guide" the OCT laser to scan the same location again. For this purpose, the first complete volume scan was set as a reference scan. The Spectralis OCT has a follow-up function to ensure that the same scanning location is identified on following visits by the tracking program. In addition, eye tracking and the high scanning speed is supposed to reduce moving artifacts. For OCT scanning, the Spectralis OCT provides an Automatic Real-Time (ART) function for increased image quality. With ART activated, multiple frames (B scans) of the same scanning location are performed during the scanning process and images are averaged for noise reduction. The number of frames can be adjusted. In this study, the ART function was turned on and three frames were acquired for each B-scan location to reduce noise and to improve image quality. Scans were acquired in the high-resolution acquisition mode.

For retinal thickness measurements, 20 × 15 degree raster scans were performed consisting of 37 high-resolution line scans. An internal fixation light was used to center of the scanning area on the fovea. Scans with low quality and a failing retinal thickness algorithm were

TABLE. Mean Retinal Thickness Values, Standard Deviations, and Coefficients of Variation for Repeated Retinal Thickness Measurements in the Nine Early Treatment of Diabetic Retinopathy Study Areas With Spectralis Optical Coherence Tomography

Area	Mean Retinal Thickness ± SD (μm)	COV (%)
1	287.1 ± 2.8	0.53
2	349.4 ± 1.8	0.52
3	335.3 ± 2.8	0.86
4	352.3 ± 1.7	0.47
5	349.9 ± 1.7	0.48
6	356.0 ± 2.0	0.56
7[a]	342.0 ± 1.3	0.38
8	348.7 ± 2.1	0.58
9	360.0 ± 1.7	0.47

COV = coefficients of variation; SD = standard deviation.
P values ranged from $P < .0017$ to $P < .0275$.
[a]COV of area 7 was significantly lower compared with areas 1, 2, 3, 5, 6, and 8.

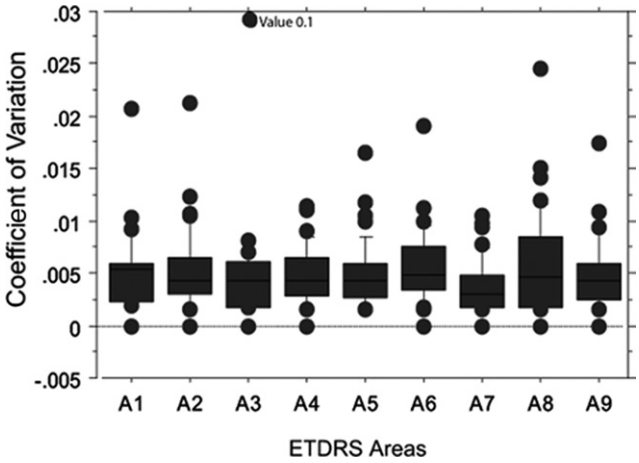

FIGURE 2. Box plots showing differences in coefficients of variation between ETDRS areas measured with Spectralis OCT. For better illustration, the scale of the *y* axis is adjusted. One data point for area 3 has been marked as being outside the scale. The actual value is given in the plot.

excluded and measurements were repeated until good quality was achieved. In addition, scans with blinks during the scanning process were excluded and repeated.

Spectralis OCT provides a software algorithm for retinal thickness measurements. Each scan was separately analyzed by using the retinal thickness algorithm to generate retinal thickness values in μm.

Retinal thickness values were calculated for nine areas corresponding to the Early Treatment Diabetic Retinopathy Study (ETDRS) areas.[14] The ETDRS plot consists of three concentric rings with diameters of 1, 2, and 3 mm. The two outer rings are divided into quadrants by two intersecting lines. Examples of a retinal thickness measurement are shown in Figure 1. More common for retinal thickness measurements is a 1, 3, and 6 mm ETDRS plot, known from Stratus OCT. However, at the time of data acquisition, the 1, 3, 6 mm pattern was not available in the Spectralis OCT software. The ETDRS grid was positioned automatically by the Spectralis OCT software and retinal thickness values were extracted as captured. No manual adjustments of the grid were performed by the operator. Coefficients of variation (COV) were calculated by calculating mean retinal thickness values and standard deviations (SDs) out of the three measurements taken for each ETDRS area and then dividing SD by mean retinal thickness values for each study subject. Differences in COV between ETDRS areas were analyzed by using paired Student *t* test.

RESULTS

THE TABLE SHOWS MEAN RETINAL THICKNESS VALUES, SDs, and COV values for the nine ETDRS areas tested. Retinal thickness measurements were highly reproducible for all ETDRS areas. Mean total retinal thickness was 342 ± 15 μm. Mean foveal thickness was 286 ± 17 μm. Mean difference between measurement 1 and 2, measurement 1 and 3, and measurement 2 and 3 for all ETDRS areas was 1.01 μm, 0.98 μm, and 0.99 μm, respectively. Mean COV was 0.54 ± 0.13%. Lowest COV was found for the temporal outer ETDRS area (area 7; COV, 0.38%). Highest COV was found for the temporal inner ETDRS area (area 3; COV, 0.86%). COV of area 7 was significantly lower compared with areas 1, 2, 3, 5, 6, and 8 (*P* values ranged from $P < .0017$ to $P < .0275$). Figure 2 shows box plots of COV values for each ETDRS area tested. Seven OCT examinations had to be repeated owing to bad scan quality, failing retinal segmentation algorithm, or blinks during the scanning process.

DISCUSSION

THE LATEST COMMERCIALLY AVAILABLE GENERATION OF FD-OCT has several advantages compared with conventional TD-OCT. High-speed imaging allows increasing the number of acquired B scans to yield greater retinal coverage and high-definition 3-dimensional images. Higher scan density leads to more detailed retinal thickness maps with less need of data interpolation. In this study, 37 B scans were used to scan a 20 × 15 degree area centered on the fovea. The Spectralis OCT has the option to increase B-scan density further for even better retinal coverage. However, higher scan density leads to longer examination time. Therefore, 37 B scans were chosen as a compromise between sufficient retinal coverage and acceptable examination duration. One has to point out that examination time is not the same as scanning speed. Scanning speed of the Spectralis OCT for a B-scan image is extremely fast,

performing up to 40,000 A scans/sec. However, B scans will only be performed if the eye tracking software recognizes the exact scanning position in the fundus image. Therefore, examination time will increase with poor fixation and eye movements. This is a major difference in the concept of image acquisition between Spectralis OCT and most other available OCT models that perform sweep scans. The concept of sweep scans is to scan a larger area (ie, 6 mm × 6 mm) in the shortest possible time without correcting for eye movements. Other commercially available FD-OCT models are able to perform up to 128 B-scan in a 6 mm × 6 mm area in about two seconds using the sweep scan technique. This leads to excellent retinal coverage in a short examination time. However, eye movements during the scanning process will most likely cause image artifacts and decrease reproducibility of retinal thickness measurements.

In addition to retinal coverage, single B-scan quality and scan resolution seem to be important factors for reproducibility of retinal thickness measurements. Higher scan resolution of FD-OCT allows a more detailed differentiation of retinal layers. Spectralis OCT has the potential of imaging with an axial resolution of up to 7 μm. In addition, it performs multiple B scans at the same scanning location during the scanning process to average images for noise reduction in order to increase image quality. Our results showed that intraobserver reproducibility of retinal thickness measurements was excellent for all ETDRS areas with a mean difference between measurements of about only 1 μm. Further studies are needed to show if the concept of image acquisition with eye tracking is superior to the sweep scan technique of other FD-OCT models. Direct comparison of the different imaging concepts might help to answer the question if retinal coverage is more important than single-scan resolution and precision in clinical routine. The excellent reproducibility of retinal thickness measurements with the Spectralis OCT can be attributable to different technical factors such as improved image resolution, imaging speed, scan coverage, or retinal segmentation algorithms. Most likely, improved reproducibility is attributable to the eye tracking mechanism and a combination of the technical improvements discussed above. However, other factors such as performance of the operator have not been tested in this study and therefore the role of the operator experience on reproducibility is unknown. In addition, no comparison was made between Spectralis OCT and Stratus OCT, as being the gold standard for retinal thickness measurements.

Reproducibility of any diagnostic test is important for diagnostic precision. In particular, reproducibility of retinal thickness measurements is critical if the device is used to monitor progression of the disease and/or therapeutic interventions. One should be aware that high diagnostic precision is not similar to high diagnostic accuracy. From this study, one can not determine if the retinal thickness measured by OCT represents the actual retinal thickness in vivo. In fact, OCT retinal thickness measurements are highly dependent on retinal segmentation algorithms, which can be different between OCT models.[15] For example, mean foveal thickness was 286 μm measured with Spectralis OCT. These values are significantly higher compared with previous findings with Stratus OCT.[15] The main difference between retinal segmentation algorithms is that Spectralis OCT includes the retinal pigment epithelium (RPE) when measuring retinal thickness, whereas Stratus OCT measures above the RPE at the inner/outer photoreceptor junction, which leads to significantly lower retinal thickness values.

Various data on OCT retinal thickness measurement reproducibility has been published previously. Bauman and associates tested reproducibility of retinal thickness measurements of a prototype instrument of the first generation OCT, showing that mean COVs ranged from 3.6% to 29.5% in the automated method. When manually adjusting the retinal thickness algorithm, COVs ranged from 3.2% to 7.2%.[16] Massin and associates used the first commercially available OCT to test reproducibility of retinal thickness measurements in nine ETDRS areas of 10 healthy eyes. Mean COVs ranged from 0.6% to 3.3%. Intraclass correlation coefficients (ICC) ranged from 0.89 to 0.99. In addition, reproducibility was tested in diabetic patients with macular edema. ICCs were always larger than 0.98 and the reproducibility was ±6% in these patients.[17] Other studies also showed good reproducibility with overall coefficients of repeatability between 1% and 2% and an expected variation of less than 11 μm between measurements.[18,19]

Other groups studied reproducibility of retinal thickness measurements by using the Stratus OCT 3 device (Carl Zeiss Meditec Inc, Dublin, California, USA). Guerses-Oezden and associates found good reproducibility with a COV of 5.8% for the Fast Macular Scan (FMS) and a COV of 4.7% for the Radial Line Scan (RLS) in healthy subjects.[20] Polito and associates tested reproducibility in healthy subjects and patients with diabetic macular edema. COVs ranged from 1.68% to 6.63% in the healthy group and from 4.84% to 8.33% in the diabetic group.[21] Paunescu and associates found ICCs for retinal thickness measurements in the nine ETDRS areas between 52% and 97% with the FMS protocol and ICCs between 35% and 96% with the RLS protocol.[22]

Direct comparison of reproducibility studies is not possible because experimental and statistical methods vary between studies. Reasons for study differences include parameters such as different measurement regions of different retinal coverage, different study groups with different retinal health, different OCT models and/or equipment settings (scan types), different operator experience, and automated or manual analysis protocols. Nevertheless, there is a clear consensus that OCT macular thickness measurements show satisfactory reproducibility and repeatability.

Our study tested intraobserver reproducibility of retinal thickness measurements within one session in healthy subjects. One would expect only little between subject variance in a group of young healthy subjects. Caution should be used when applying these data on older subjects or patients with retinal diseases who are expected to have a greater between subject variance. Therefore, additional studies are needed testing reproducibility of retinal thickness measurements of the Spectralis OCT in patients with macular diseases. In addition, further studies are needed to test intersession- and interobserver reproducibility of retinal thickness measurements before Spectralis OCT can be safely used as a tool for monitoring retinal thickness.

Our data showed a significantly lower COV for area 7, which represents the temporal outer quadrant, compared with areas 1, 2, 3, 5, 6, and 8. The reason for that is not clear, especially as areas 4 and 9 for which significance could not be shown are located inferior and nasal to the fovea. Knighton and associates found lower reproducibility nasally compared with other quadrants when measuring RNFL thickness with OCT.[23] Differences in the angle of incidence of the illuminating beam might have an influence on scan-image quality and therefore on the retinal segmentation algorithm. However, from a clinical perspective, differences between measurements were only marginal even in area three with the highest COV. Mean differences of about 1 μm between measurements might not have any clinical relevance.

In conclusion, retinal thickness measurements could successfully be performed in all ETDRS areas. Our results indicate excellent intraobserver reproducibility for retinal thickness measurements performed by the Spectralis OCT in healthy controls.

THE AUTHORS INDICATE NO FINANCIAL SUPPORT OR FINANCIAL CONFLICT OF INTEREST. INVOLVED IN DESIGN OF STUDY (M.N.M., V.S.); conduct of study (M.N.M., S.D., P.K.); collection and management of data (S.D., P.K.); interpretation of data (M.N.M., V.S.); preparation of the manuscript (M.N.M., V.S.); and approval of the final manuscript (M.N.M., S.D., P.K., V.S.). All subjects gave informed consent to participate in the study that was conducted in accordance with the Institutional Review Board of the University Hospital Zurich and the tenets of the Declaration of Helsinki.

REFERENCES

1. Jean B, Frohn A, Thiel JH. Laser scanning in ophthalmology. Fortschr Ophthalmol 1990;87:158–167.
2. Huang D, Swanson EA, Lin CP, et al. Optical coherence tomography. Science 1991;254:1178–1181.
3. Hee MR, Izatt JA, Swanson EA, et al. Optical coherence tomography of the human retina. Arch Ophthalmol 1995; 113:325–332.
4. Puliafito Ca, Hee MR, Lin CP, et al. Imaging of macular diseases with optical coherence tomography. Ophthalmology 1995;102:217–229.
5. Choma MA, Sarunic MV, Yang C, Izatt JA. Sensitivity advantage of swept source and Fourier-domain optical coherence tomography. Opt Express 2003;11:2183–2189.
6. Wojtkowski M, Srinivasan V, Fujimoto JG, et al. Three-dimensional retinal imaging with high-speed ultra-high resolution optical coherence tomography. Ophthalmology 2005;112:1734–1746.
7. Wojtkowski M, Srinivasan V, Ko T, Fujimoto JG, Kowalczyk A, Duker JS. Ultra-high resolution, high-speed, Fourier-domain optical coherence tomography and methods for dispersion compensation. Opt Express 2004;12:2404–2422.
8. Wojtkowski M, Srinivasan V, Ko T, et al. High-speed, ultra-high resolution retinal imaging using spectral/Fourier-domain OCT. Conf Lasers Electrooptics 2005;3:2058–2060.
9. Srinivasan V, Wojtkowski M, Witkin AJ, et al. High-definition and three-dimensional imaging of macular pathologies with high-speed ultra-high resolution optical coherence tomography. Ophthalmology 2006;113:2054–2065.
10. Alam S, Zawadzki RJ, Choi S, et al. Clinical application of rapid serial Fourier-domain optical coherence tomography for macular imaging. Ophthalmology 2006;113:1425–1431.
11. Schmidt-Erfurth U, Leitgeb RA, Michels S, et al. Three-dimensional ultra-high resolution optical coherence tomography of macular diseases. Invest Ophthalmol Vis Sci 2005; 46:3393–3402.
12. Ahlers C, Geitzenauer W, Simader C, et al. New perspectives in diagnostics. High-resolution optical coherence tomography of age-related macular degeneration. Ophthalmologe 2008;105: 248–254.
13. Wolf-Schnurrbusch UE, Enzmann V, Brinkmann CK, Wolf S. Morphological changes in patients with geographic atrophy assessed with a novel spectral OCT-SLO combination. Invest Ophthalmol Vis Sci 2008;49:3095–3099.
14. Early Treatment Diabetic Retinopathy Study esearch Group. Photocoagulation for diabetic macular edema. Early Treatment Diabetic Retinopathy Study Report No. 1. 1985;103: 1796–1806.
15. Menke MN, Dabov S, Sturm V. Comparison of three different OCT models for total macular thickness measurements in healthy controls. Ophthalmologica 2008. Forthcoming.
16. Baumann M, Gentile RC, Liebmann JM, Ritch R. Reproducibility of retinal thickness measurements in normal eyes using optical coherence tomography. Ophthalmic Surg Lasers 1998;29:280–285.
17. Massin P, Vicaut E, Haouchine B, Erginay A, Paques M, Gaudric A. Reproducibility of retinal mapping using optical coherence tomography. Arch Ophthalmol 2001;119:1135–1142.
18. Muscat S, Parks S, Kemp E, Keating D. Repeatability and reproducibility of macular thickness measurements with the Humphrey OCT system. Invest Ophthalmol Vis Sci 2002; 43:490–495.
19. Koozekanani D, Roberts C, Katz SE, Herderick EE. Intersession Repeatability of macular thickness measurements with the Humphrey 2000 OCT. Invest Ophthalmol Vis Sci 2000;41:1486–1491.

20. Gürses-Oezden R, Teng C, Vessani R, Zafar S, Liebmann JM, Ritch R. Macular and retinal nerve fiber layer thickness measurement reproducibility using optical coherence tomography (OCT 3). J Glaucoma 2004;13:238–244.
21. Polito A, Del Borrello M, Isola M, Zemella N, Bandello F. Repeatability and reproducibility of fast macular thickness mapping with Stratus optical coherence tomography. Arch Ophthalmol 2005;123:1330–1337.
22. Paunescu LA, Schuman JS, Price LL, et al. Reproducibility of nerve fiber thickness, macular thickness, and optic nerve head measurements using Stratus OCT. Invest Ophthalmol Vis Sci 2004;45:1716–1724.
23. Knighton RW, Qian C. An optical model of the human retina nerve fiber layer: implications of directional reflectance for variability of clinical measurements. J Glaucoma 2000;9:56–62.