

Oral Fluorescein Angiography with the Confocal Scanning Laser Ophthalmoscope

Claudio R. Garcia, MD,¹ Maria E. Rivero, MD,¹ Dirk-Uwe Bartsch, PhD,¹ Satoshi Ishiko, MD, PhD,² Akira Takamiya, MD,² Katsuhiko Fukui, MS,² Hiroyuki Hirokawa, MD, PhD,² Thomas Clark, BA,¹ Akitoshi Yoshida, MD, PhD,² William R. Freeman, MD¹

Objective: To evaluate the efficacy of oral fluorescein angiography with a confocal scanning laser ophthalmoscope (SLO) system.

Design: Comparative case series.

Participants: The authors used a confocal SLO (Heidelberg Retina Angiograph [HRA]) to perform oral fluorescein angiography in 47 patients, 13 of whom were without any retinal disease and 34 with a variety of retinal diseases including macular holes and pucker, inflammatory diseases, retinal vascular diseases, and age-related macular degeneration. The images were also compared to images taken with a fundus camera after intravenous fluorescein injections in patients on whom both studies were done.

Intervention: Color fundus photographs were taken of each eye (30° fundus camera) before drinking 4 ml of 25% sodium fluorescein mixed with 60 ml of orange juice. After oral fluorescein ingestion, images of each eye were taken with a fundus camera (TriX film) and the HRA (using 512- × 512-pixel resolution). The images were repeated at 0-, 2.5-, 5-, 7.5-, 10-, 12.5-, 15-, 20-, 25-, and 30-minute intervals. Twenty of the 47 patients underwent intravenous fluorescein angiography performed with the fundus camera.

Main Outcome Measure: Images were analyzed by a masked reader, and foveal avascular zone visualization, branch retinal vessel identification, and image quality were scored. Statistical analysis was performed with a *t* test for paired data with a two-tailed test of significance ($\alpha = 0.05$).

Results: Foveal avascular zone was 100% as seen in 16 eyes (47%) in the HRA machine versus 1 eye (2%) in the conventional fundus camera ($P < 0.0001$). The third-order branch retinal vessels were identified in 59% of eyes in the HRA versus 26% in the fundus camera group ($P < 0.0001$), and the image quality was considered comparable to an intravenous angiogram in 47% with the HRA versus 9% with the conventional fundus camera ($P < 0.0001$).

Conclusions: Oral fluorescein angiography using the HRA produces sufficiently detailed images to diagnose, treat, and follow many types of retinal pathology. *Ophthalmology* 1999;106:1114-1118

The compound sodium fluorescein was first synthesized in 1871 but only in 1961 was the concept of intravenous (IV) fluorescein angiography as a new diagnostic tool introduced. Since then, it has become widely used and accepted to provide detailed visualization of the retinal and choroidal circulation.¹

Complications from IV fluorescein injections have been reported² and have been divided into systemic and local

types. Nausea is the most common symptom among the systemic side effects. Itching, skin rash, and, less frequently, bronchospasm may occur, especially if patients have a medical history of asthma, hay fever, or allergies. Less-common complications include dizziness, cold sweats, and fainting. Anaphylactic shock and acute pulmonary edema are rare (0.05%)² and are treated as life-threatening situations. Local complications are related to extravasation of dye at the injection site and may range from a local skin reaction to thrombophlebitis.

In patients technically or otherwise unsuitable for IV injections, it has been difficult to adequately visualize the retinal and choroidal circulations to diagnose and treat pathology.³ Oral fluorescein angiography has been proposed as an alternative to IV angiography and to avoid its complications.²⁻⁵ Several doses have been tested to achieve the best image quality using the fundus camera.^{6,7} A mild skin reaction has been reported with an oral dose in a patient with personal and familial history of atopic eczema.⁸ However, it is generally assumed that the adverse reaction rate and severity is less with oral than with IV fluorescein angiography. The phenomenon of lower incidence in adverse reaction to orally administered agent versus IV route

Originally received: August 24, 1998.

Revision accepted: January 14, 1999.

Manuscript no. 98533.

¹ University of California, San Diego; Department of Ophthalmology, Shiley Eye Center, San Diego, California.

² Department of Ophthalmology, Asahikawa Medical College, Asahikawa, Japan.

Presented in part at the Association for Research in Vision and Ophthalmology annual meeting, Fort Lauderdale, Florida, May 1998, and at the American Academy of Ophthalmology annual meeting, New Orleans, Louisiana, November 1998.

Supported by NIH EY07366 (WRF).

Dr. Bartsch is a part-time consultant for Heidelberg Engineering.

Address correspondence to William R. Freeman, MD, UCSD, Shiley Eye Center, 9415 Campus Point Dr., La Jolla, CA 92093-0946.

Table 1. Diagnosis Confirmed on Heidelberg Retina Angiograph Oral Angiography

Disease	No. of Cases
CME	6
ERM	2
ARMD	8
Angioid streaks	1
Macular drusen	1
Panuveitis	1
Retinal vasculitis	1
NPDR	4
PDR	0
DME	1
AMPPPE	1
BRVO	2
Anterior uveitis (HLA-B27+)	1
Macular hole	1
Perifoveal telangiectasia	1
Control patients	13
Total	47

CME = cystoid macular edema; ERM = epiretinal membrane; ARMD = age-related macular degeneration; NPDR = nonproliferative diabetic retinopathy; PDR = proliferative diabetic retinopathy; DME = diabetic macular edema; AMPPPE = acute multifocal placoid pigmentary retinopathy; BRVO = branch retinal vein occlusion.

is well documented in the case of penicillin. Oral administration of therapeutic doses of penicillin is less likely to produce a systemic allergic reaction than parenteral administration. Indeed, the incidence of severe allergic reaction is far less with oral than with parenterally administered drugs of many types.⁹

Allergic reactions to fluorescein commonly occur at the first exposure, signifying an anaphylactoid reaction, in contrast to a true anaphylactic reaction, which is immunoglobulin E (IgE) antibody-mediated after an initial exposure to a drug.¹⁰ The incidence of allergic reactions to fluorescein varies by severity of reaction. For severe reactions (e.g., cardiac, respiratory, or similar severe reactions), the incidence rate has been estimated to be 1 in 2000 angiograms with death occurring in 1 in 220,000 angiograms.¹¹ These estimations are from surveys and not from prospective studies. Therefore, it is reasonable to assume that orally

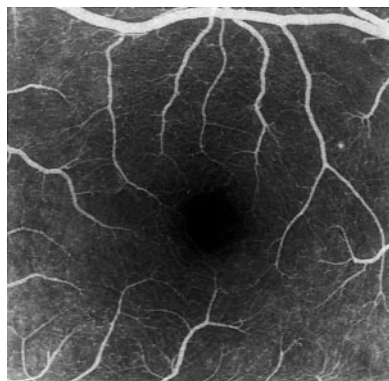


Figure 1. Foveal avascular zone is well visualized in a 25-year-old subject with no ocular pathology. Angiography was performed with oral fluorescein using the Heidelberg Retina Angiograph.

administered fluorescein is less dangerous than IV fluorescein in terms of allergic reactions.

We have studied the oral administration of fluorescein using an alternative imaging device, the Heidelberg Retinal Angiograph (HRA), a confocal scanning laser ophthalmoscope (SLO). We have previously described the use of this digital device using IV injections of fluorescein and indocyanine green.¹²⁻¹⁴ Advantages of this instrument include extremely high sensitivity of the detector, a less-complex optical pathway, and the ability to scan the retina with a laser beam, which has a higher light yield than a conventional camera to stimulate fluorescence, thus providing a stronger fluorescence signal and high contrast due to confocal optics. We hypothesized, therefore, that this system would allow good quality images of the retinal and choroidal circulation after oral fluorescein administration. We therefore compared oral fluorescein angiography using the confocal SLO to oral and IV angiography using a conventional fundus camera.

Materials and Methods

Forty-seven subjects were examined with a confocal SLO (Heidelberg Retinal Angiograph; Heidelberg Engineering, Carlsbad, CA) and a 30° fundus and fluorescein angiogram camera (Carl Zeiss Inc., San Leandro, CA). Studies were performed at two university hospital referral centers (Shiley Eye Center, La Jolla, CA, and Asahikawa Medical College, Asahikawa, Japan) between February 1997 and March 1998. Thirteen of the total subjects were healthy young volunteers (age, 25–35 years) from the Asahikawa Medical College.

Twenty male and 14 female patients ranging in age from 40 to 89 years underwent oral fluorescein angiography using both fundus camera and HRA machines for the specific pathologies listed in Table 1. The most affected imaged eye was the right eye in 12 cases, the left eye in 5 cases, and both eyes in 17 cases. For statistical purposes, one eye was analyzed per patient. Patients were not asked to fast before the procedure, but some had done so. All angiograms were clinically indicated, except in volunteers imaged at the Asahikawa Medical College, where informed consent was obtained.

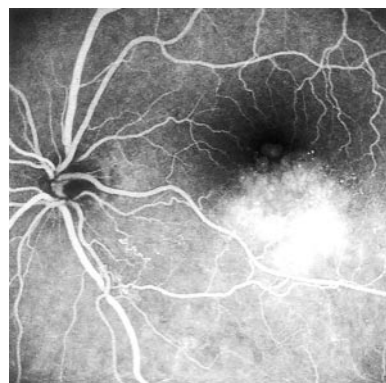


Figure 2. Details of retinal vascular changes in a patient with an inferotemporal branch retinal vein occlusion. Note retinal vascular remodeling at site of occlusion 1 disc diameter from optic nerve along inferotemporal vein. Cystoid macular edema is seen. The image is taken 25 minutes after ingestion of oral fluorescein.

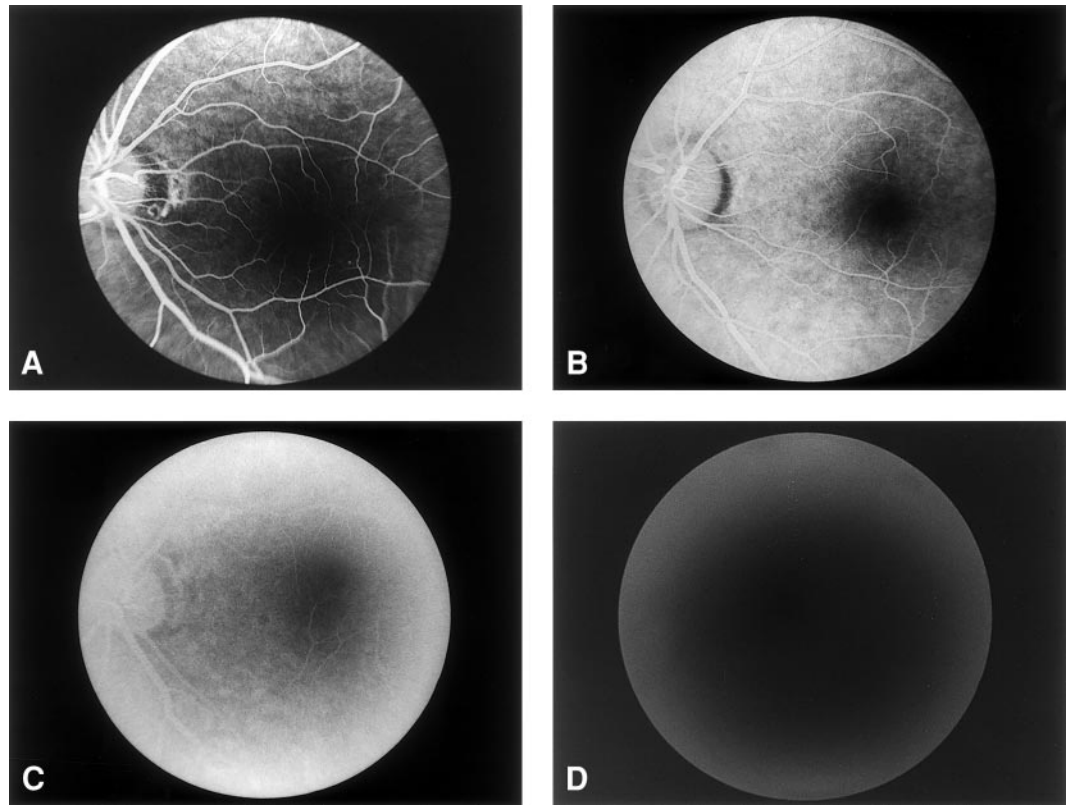


Figure 3. Grade scale for image quality analysis: (A) upper left, grade 3; (B) upper right, grade 2; (C) lower left, grade 1; (D) lower right, grade 0.

Pupillary dilation was performed with tropicamide 1% and phenylephrine hydrochloride 2.5% for all imaging studies. For oral fluorescein angiography, two ampules of 25% fluorescein (Fluorescite; Alcon Pharmaceuticals, Ft. Worth, TX [25 mg/ml]), containing 1.0 g of the sodium salt, were mixed with 30 ml of orange juice. After ingestion, an additional 30 ml of pure orange juice without fluorescein was ingested to clear the taste.

For oral angiography, a sequence of photographs and electronic images was taken at timepoints of 0, 2.5, 5, 7.5, 10, 12.5, 15, 20, 25, and 30 minutes. The patients were imaged with both machines to record images that were temporally at similar times and thus comparable.

Once the imaging was completed, film was processed with Kodak D-19 Developer (Eastman Kodak, Rochester, NY) for 11.2 minutes at 28.8°C, and a positive print was made on Kodalith 8- × 10-inch contact film. The HRA images were stored on the hard disc drive of the computer and subsequently transferred to an

optical disc. Intravenous angiograms with the conventional fundus camera were previously performed in 20 patients within 2 weeks of the oral angiography.

To analyze and compare the two systems, we performed a masked comparison of foveal avascular zone (FAZ) visualization, branch retinal vessel identification, and image quality. The FAZ visualization was described as a percentage of FAZ seen (Fig 1). To quantitate the retinal vessels, they were graded by the order of branch vessels seen. If the third-branch order was seen, it was graded "3." If only the second-order branches could be easily seen, we graded the angiogram "2." If only the first branch, the grade was "1" and grade zero was used for those angiograms on which even the first branch could not be seen (Fig 2); this was graded in the midphase of the angiogram. The image quality was graded in four categories: 3 = excellent image quality (details of all vessels and FAZ comparable to IV angiogram); 2 = moderate image quality (good image quality with loss of details of the small vessels

Table 2. Percentage of Foveal Avascular Zone Visualized: No. (%) of Patients

%	Oral Film	Oral HRA	IV Film*
0-10	23 (67)	9 (26)	5/20 (25)
11-30	3 (9)	3 (9)	2/20 (10)
31-50	4 (12)	3 (9)	1/20 (5)
51-70	3 (9)	3 (9)	1/20 (5)
71-100	1 (3)	16 (47)	11/20 (55)

* Total number of patients was 34. IV angiography was performed in 20 of these patients; thus, there were only 20 cases where the comparison of IV to oral HRA could be performed. Oral film vs. oral HRA, $P < 0.0001$ (paired t test); IV film vs. oral HRA, $P = 0.09$ (paired t test).

Table 3. Branch Retinal Vessel Visualization

Method	Grade 3 (%)	Grade 2 (%)	Grade 1 (%)	Grade 0 (%)
Oral film angiogram	26	21	9	44
Oral HRA angiogram	59	18	15	8
IV film angiogram	75	10	10	5

Grade 3 = third branch order seen; Grade 2 = second order branches seen; Grade 1 = first order branch seen; Grade 0 = even the first branch could not be seen.

Oral film vs. oral HRA, $P < 0.0001$ (paired t test); IV film vs. oral HRA, $P < 0.8$ (paired t test).

Table 4. Image Quality Analyzed

Grade	Oral Film Angiogram (%)	Oral HRA Angiogram (%)	IV Film Angiogram (%)
0	30	3	5
1	23	21	15
2	38	29	20
3	9	47	60

Grade 3 = excellent image quality; Grade 2 = moderate image quality; Grade 1 = poor image quality; Grade 0 = no useful image.

Oral film vs. oral HRA, $P < 0.0001$ (paired t test); IV film vs. oral HRA, $P = 0.6$ (paired t test).

and capillaries); 1 = poor image quality (macula and optic disc seen); and 0 = no useful image (Fig 3).

The pictures were chosen from corresponding timepoints in both machines. Images taken with the HRA were recorded on 35-mm transparency film (Fujichrome 100 ASA, Fuji, Tokyo, Japan) using a digital film recorder (Personal LFR Plus; Lasergraphics, Irvine, CA) to provide a hard copy of the acquired images. The 35-mm black-and-white transparencies acquired with the HRA machine were square images measuring 2.3×2.3 cm on the transparency film. The fundus camera image on the black-and-white film was a round 2.6-cm-diameter image. We masked both images with a black mask containing a 2.25-cm-diameter round opening. This allowed both systems to be projected for analysis while masking features that would identify the camera types. A t test for paired data with a two-tailed test of significance ($\alpha = 0.05$) was calculated to estimate differences between continuous values. Approval by the University of California, San Diego Human Subjects Committee, was obtained for this study.

Results

After oral administration, the presence of fluorescein in the major retinal vessels was detected between 5 and 7 minutes, and the best images that allowed definition of macular and submacular vascular structures were at 15 to 30 minutes after the ingestion of the dye. There was no difference in image quality or time to fluorescein appearance in patients who fasted before fluorescein ingestion versus those who did not. However, we did not study patients immediately after meals.⁵

The percentage of FAZ visualized with the HRA was significantly greater than the percentage of FAZ visualized with the fundus camera ($P < 0.0001$). The percentage of FAZ visualized by oral HRA was slightly less than with IV fundus camera, but this was not significantly different ($P < 0.09$) (Table 2). The number and size of branch retinal vessels that could be seen by oral HRA were greater and finer than with the oral fundus camera ($P < 0.0001$). The third-branch retinal vessel values taken by oral HRA were similar to the third-branch retinal vessel values for the IV fundus camera values ($P < 0.8$) (Table 3). The image quality grading showed better quality for the images performed with the oral HRA (Table 4) when compared to the fundus camera ($P < 0.0001$) but have shown similar values when the comparison was performed between oral HRA and IV fundus camera ($P < 0.6$).

For diseases in which leakage occurs (i.e., cystoid macular edema or branch retinal vein occlusion), leakage was seen as early as 12 to 15 minutes after ingestion, and the leakage was more intense from 17 to 32 minutes. An arterial-filling phase could not be clearly seen nor could the venous laminar flow phase be defined

with the oral fluorescein angiogram. The retinal pathology could be adequately visualized to allow diagnosis and treatment in 82% of the cases when performing the oral angiography with the HRA.

Discussion

Intravenous injection of fluorescein results in a high concentration of the fluorescein in plasma. The contrast medium reaches the eye and provides fine details of chorioretinal anatomy and circulation, and it is also possible to show the physiologic barriers of the eye.

In an attempt to avoid the complications, discomfort, and difficulty associated with IV injections of fluorescein and to allow studies of the retinal and choroidal circulation in persons technically or physically unsuitable for IV injections (e.g., children or patients with difficult venous access), oral administration of fluorescein has been attempted. Oral fluorescein angiography was first performed by Burke, but the diffusion of the dye in the aqueous humor and alterations of the physiologic barriers of the fundus assessed with this technique were described by Kelley and Kincaid. The most common method of administration has been that of ampules dissolved in lemon or orange juice. The look and taste are unpleasant, even when mixed with juice. For this reason, other forms of administration, such as gel capsules, have been studied.⁵

Previous studies of oral fluorescein angiography have used a conventional fundus camera and concluded that oral angiographic images were useful only in cases in which low-quality late images were acceptable, as in patients with cystoid macular edema, central serous retinopathy, and retinal pigment epithelial detachments. The ideal oral dose of the salt has been suggested to be 30 mg/kg body weight⁷ compared to the 500-mg dose used for IV injections.

Fluorescein has no effect on systemic metabolism. It is metabolized by the liver and excreted by the kidneys. Intravenous doses of 300 mg/kg have been shown to be potentially lethal in rabbits. The administered dose to the patients was clearly nontoxic and over an order of magnitude smaller than the potentially lethal IV dose, and no side effects were observed. Our study has shown that the pres-

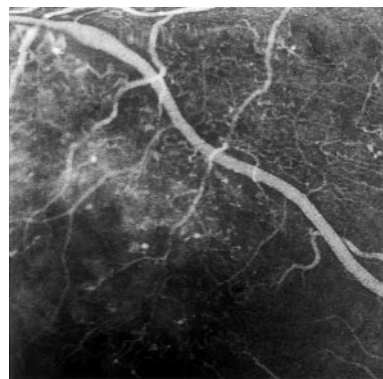


Figure 4. Details of retinal microcirculation in a patient with diabetes. Areas of capillary dropout, microaneurysms, and vascular tortuosity are seen along retinal vein superotemporal to macula.

ence of dye in the retinal circulation is detected as early as 5 to 7 minutes, but the best images were recorded at 15 to 30 minutes. Many details of the retinal circulation seen with the HRA (Fig 4) could not be reproduced with the fundus camera using oral dye.

More important, the 30° frames of the HRA were taken with a 512- × 512-pixel resolution. Conventional fundus cameras typically offer rounded 20°, 30°, and 50° views. The HRA offers square fields of view of 10 × 10°, 20 × 20°, and 30 × 30°. A field of 10 × 10° corresponds to 15° diagonally; 20 × 20° corresponds to 28° diagonally, and 30 × 30° corresponds to 42° diagonally. The HRA has a pixelation of 256 by 256 or 512 by 512 pixels. At 512- × 512 pixels in a 10° field, each pixel has the dimension of approximately 5 × 5 μm. This dimension is smaller than the resolution limit of the eye. In film-based fundus cameras, this pixelation is equivalent to 1024- × 1024 pixels within a 30° field of view. Little additional information can be gained with conventional fundus camera at pixelations of more than 1024- × 1024 pixels at 30° because the optical resolution is limited by the eye to approximately 10 to 15 μm on the fundus, and the area corresponding to each such pixel would be less than that dimension.

Our study has shown that confocal SLO imaging systems have enough sensitivity and contrast to allow adequate fluorescein angiography in many cases. Although the image detail is not equal to IV angiography in all cases, they both are far superior to what has been reported in the past as validated by our own comparisons to oral angiography using a conventional fundus camera. For many clinical purposes, oral angiography using the HRA produces adequate images that allow diagnosis, follow-up, and treatment of many retinal pathologies. Further studies need to be performed on a larger patient cohort to determine the specific aspects of the dynamics of the oral fluorescein angiogram, particularly regarding the adequacy of visualizing subretinal neovascular membranes. Such studies in patients with acute choroidal neovascularization will be difficult. To compare the two techniques would require a 1- to 2-day interval between oral and IV fluorescein angiography to allow fluorescein to clear from fundus structures of interest. In cases of acute choroidal neovascularization, it may be difficult to study both techniques, given the relatively urgent need for laser treatment.

References

1. Eustace P, Travers S, Mooney D. Oral fluorescein angiography in disc oedema. *Bull Soc Belge Ophtalmol* 1984;211:35-41.
2. Watson AP, Rosen ES. Oral fluorescein angiography: reassessment of its relative safety and evaluation of optimum conditions with use of capsules. *Br J Ophthalmol* 1990;74:458-61.
3. Azad R, Nayak BK, Tewari HK, Khosla PK. Oral fluorescein angiography. *Indian J Ophthalmol* 1984;32:415-7.
4. Balogh VJ. The use of oral fluorescein angiography in idiopathic central serous choroidopathy. *J Am Optom Assoc* 1986;57:909-13.
5. Quentel G, Attali P, Coscas G. Angiographie à la fluorescéine par voie orale. Intérêts et limites [in French]. *Bull Soc Ophtalmol Fr* 1984;84:567-8.
6. Gómez-Ulla F, Malvar A, Parafita M, et al. Oral fluorescein angiography and fluoroscopy: determination of plasma fluorescein levels and clinical application. *Optom Vis Sci* 1992;69:986-90.
7. Zhang SL, Li RX. The effect of dosage on oral fluorescein angiography of the fundus [in Chinese]. *Chung Hua Yen Ko Tsa Chih* 1992;28:166-7.
8. Kinsella FP, Mooney DJ. Anaphylaxis following oral fluorescein angiography. *Am J Ophthalmol* 1988;106:745-6.
9. Sullivan TJ. Drug Allergy. In: Middleton E Jr, Reed CE, Ellis EF, et al, eds. *Allergy: Principles and Practice*, 4th ed. St. Louis: Mosby, 1993; V.II, chap. 69.
10. Pacurariu RI. Low incidence of side effects following intravenous fluorescein angiography. *Ann Ophthalmol* 1982;14:32-6.
11. Yannuzzi LA, Rohrer KT, Tindel LJ, et al. Fluorescein angiography complication survey. *Ophthalmology* 1986;93:611-7.
12. Bartsch DU, Weinreb RN, Zinser G, Freeman WR. Confocal scanning infrared laser ophthalmoscopy for indocyanine green angiography. *Am J Ophthalmol* 1995;120:642-51.
13. Freeman WR, Bartsch DU, Mueller AJ, et al. Simultaneous indocyanine green and fluorescein angiography using a confocal scanning laser ophthalmoscope. *Arch Ophthalmol* 1998;116:455-63.
14. Mueller AJ, Bartsch DU, Folberg R, et al. Imaging the microvasculature of choroidal melanomas with confocal indocyanine green scanning laser ophthalmoscopy. *Arch Ophthalmol* 1998;116:31-9.